DOSE REDUCTION BY ELECTRONIC RADIOGRAPHY

Donald Sashin, Ph.D., E.R. Heinz, M.D. and E.J. Sternglass, Ph.D.
Department of Radiology, School of Medicine, University of Pittsburgh
Pittsburgh, Pennsylvania 15261

ABSTRACT

High resolution electronic radiography has been developed for use in diagnostic radiographic and fluoroscopic procedures. These methods are being developed for IVP pelvimetry, intrauterine transfusions, gastrointestinal examinations,stereotaxic procedures, and selective catheterization. Preliminary clinical data show that dose reduction can range from 10 to 10,000 times depending on the resolution requirements of the particular examination.

I. INTRODUCTION

The use of new electronic image amplifiers (1) television systems, and electronic recording devices represents a major advance in radiological techniques by allowing a significant reduction in radiation dose and an improvement in the diagnostic quality of images. The medical radiation dose in diagnostic procedures (2) has become of increasing concern as the result of mounting evidence for serious somatic effects of diagnostic x-rays such as an increased incidence of leukemia in young children whose mothers received diagnostic x-ray examinations during pregnancy,(3) as well as increasing evidence for a growing genetically significant dose from diagnostic procedures. Recent calculations have estimated that from 3,000 to 6,000 cancer deaths annually are caused by exposure of the American public to present levels of diagnostic x-rays. In addition, ill health results from genetic damage caused by the exposure.(4)

At resolutions adequate for most diagnostic purposes the amount of radiation required for radiography, even when utilizing the best intensifier screens and fastest films, is far in excess of what would be required if x-ray quanta could be utilized as efficiently as in present electronic image intensifiers for fluoroscopy. This arises from the fact that although one or more grains are typically sensitized for each x-ray photon absorbed in the intensifying phosphor screen, the presence of unavoidable fog at low densities causes these grains to be lost in the statistical fluctuations of the background grains.

With a high gain x-ray phosphor and television camera system, a detectable signal above noise can be produced for single x-ray quanta absorbed in the phosphor screen. This high efficiency of visible photon conversion in the photo-electric effect, amounting to as much as 65%, is constant for all fluxes of x-ray photons, independent of both of accumulated dose and does-rate, unlike the case of film where the quantum efficiency for visible photons is generally less than 0.1 percent due to the inherent non-linearity of the photographic process since 5 to 10 visible-light photons must be absorbed by a given grain before it becomes developable.

Theoretical considerations and experimental evidence indicate that the ultimate limitations to the reduction in x-ray dose set by quantum fluctuations of the x-ray flux permit substantial reductions far below the doses presently realized with films. Even at resolutions of about 4 lp/mm and a contrast of 5 to 20% actually utilized in most clinical radiographs, significant dose reductions should be possible by the use of electronic radiography which maximizes the utilization of x-rays while minimizing the radiation exposure to the patient in diagnostic procedures. This method permits the radiologist to reduce the patient exposure depending on the resolution requirement of a particular examination. With film relatively large dose are required to attain adequate densities which

reduces the image quality because of focal spot and motion blurring. In film radiography the inability to achieve short exposures with very small focal spots limits magnification techniques, as well as the "air-gap" technique. Contrast enhancement by the use of heavy selective filtration to produce monochromatic radiation from the continuous spectrum of x-rays is severely limited by the high radiation exposure required by film. All these limitations are reduced by the substitution of the more efficient electronic technique for recording radiographic images, improving the diagnostic value of radiograms beyond that possible with chemical photography.

Basically, electronic radiography is an x-ray recording technique which involves the substitution of the highly effective photo-electric effect for the relatively inefficient photo-chemical effect taking place in film.

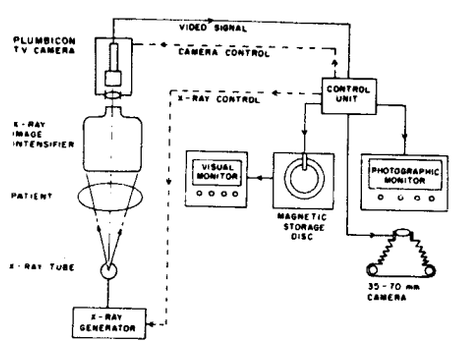

Figure 1: Block Diagram of the Apparatus

Electronic radiographs are recorded as follows (Figure 1). X-rays produced in the usual manner are incident on the object, and those that penetrate impinge upon an x-ray luminescent phosphor screen of an x-ray image intensifier. Light emitted by the phosphor screen releases photoelectrons from a thin photo-cathode in optical contact with the x-ray phosphor. The photo-electrons released are accelerated by some 30,000 volts and focused onto a small output phosphor where they give rise to a greatly brightened image which is viewed by a television camera. The optical image on the output phosphor of the intensifier is converted to an electronic charge pattern on the target of the camera tube. The charge pattern produced on the target is converted to a video-signal by means of a scanning electron beam and recorded in three alternative methods. (1) The electrical signal of one television frame or a series of frames may be recorded on a magnetic disc and then immediately replayed over a flicker-free frozen radiographic image for continuous viewing without appreciable deterioration. (2) The signal representing an individual farme may be recorded on a silicon image storage tube and immediately replayed over a TV monitor. However, this image gradually deteriorates and is completely erased after 5 to 10 minutes of continuous viewing. (3) A single video frame or many frames may be photographed by camera focused on a remote television monitor.

Systems incorporating these components have increased diagnostic information, reduced procedure time, decreased patient trauma, reduced radiation dose and permitted new types of procedures to be undertaken. Electronic radiography is used in gastrointestinal examinations [5] selective catheterization[6] pelvimetry [7] and repair of intra cranial aneurysms and arteriovenous malformations[8].

In addition to improving the image quality, electronic radiography eliminates some other disadvantages of film radiography such as chemical processing time and expenses and permits a reduction of radiation exposure to the absolute minimum dictated by the quantum noise limit for the particular degree of detail and contrast needed for a given purpose.

II. ELECTRONIC SPOT IMAGING FOR GASTROINTESTINAL FLUOROSCOPY

We have developed a high resolution technique of electronic spot imaging, to replace standard spot-filming in gastrointestinal fluoroscopy. The system consists of a standard

fluoroscopic unit electronically interfaced to a magnetic disc recorder. Key components of the system are: (1) a small focal spot x-ray tube, (2) a CsI intensifier tube, (3) a Plumbicon television camera, and (4) a 400 track magnetic disc recorder. The principle of operation is the storage of single television fluoroscopic frames on individual tracks of a magnetic disc. Once recorded, the signals can be reviewed over a television monitor at the end of the examination and later photographed for a permanent record.

At the start of an examination the unit is placed in the fluoro-record mode which allows monitoring of dynamic motion. A standard television fluoroscopic image is first generated by depressing a foot pedal. Further depression of the pedal closes a second switch which automatically boosts x-ray output, and records a single television fluoroscopic frame on the magnetic disc. In contrast to normal spot-filming this recording technique does not interrupt the fluoroscopic sequence and permits the fluoroscopist to monitor the patient continuously. At the termination of an examination, the fluoroscopist can review the images by turning the hand switch to reverse. Then, every time the foot pedal is depressed, the recording head of the disc recorder is moved one track in the reverse direction and the monitor displays a frozen radiograph previously recorded as a flicker-free electronic spot image. After arriving at the initial image of a given examination the fluoroscopist by switching to the forward mode, may then leisurely study each image in the order that it was recorded. Image brightness and contrast can be adjusted on the television monitor. After checking the recorded images for completeness, the fluoroscopist is ready to proceed with the next examination. At the end of a day's fluoroscopy, the disc recorder is moved to the reporting area, where corresponding radiographs are displayed. The electronic spot images and overhead films are then reviewed before rendering a final diagnostic report. Key electronic spot images are photographed to provide a permanent record while allowing reuse of the magnetic disc.

The radiation exposure for a single electronic spot image is about 1/50 of that required for conventional film-screen cassettes and 1/5 of the requirement for 105mm. spot-filming respectively. The exact dose depends on the resolution and contrast requirements of the particular examination.

We have compared the electronic technique to 105mm. spot-filming with regard to diagnostic accuracy in a clinical study (Fig. 2,3). Small ulcers (1-5mm. in diameter), varices, colonic polyps, various diverticula and other pathology were readily diagnosed by both techniques. In a double blind study six radiologists independently arrived at diagnoses in 21 patients. Their interpretations were then scored against those of the fluoroscopist and evaluated using the analysis of variance. The average correct scores were 76.5% and 75.5% for the electronic spot imaging and 105mm spot-filming methods respectively. Although both methods yield clinically acceptable results, we have found electronic spot imaging to be a more convenient technique of recording and reviewing fluoroscopic information.

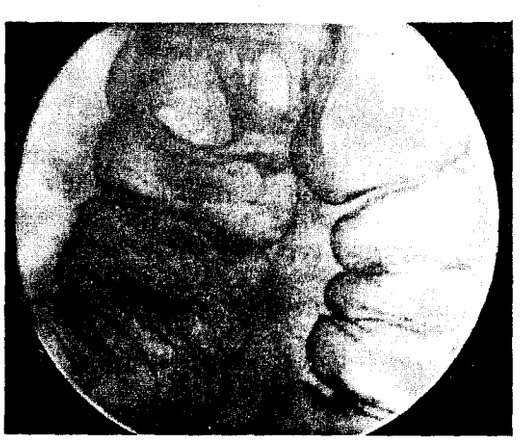

Figure 2: Electronic Spot Image of Splenic Flexure Taken During Double Contrast Barium Enema

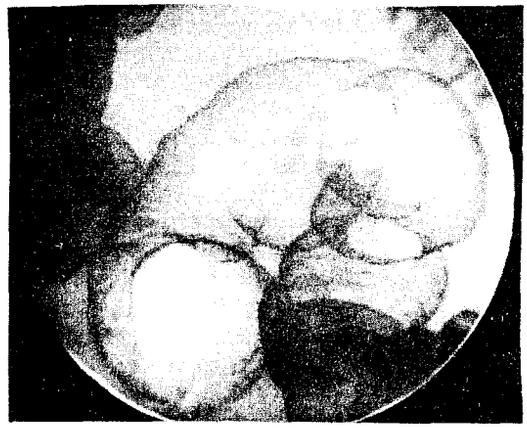

Figure 3: Electronic Spot Image Taken of Sigmoid Colon

III. PELVIMETRY WITH SMALL RADIATION EXPOSURE

The apparatus for polaroid television technique consists of a polaroid camera focused at a remote television monitor of a standard television fluoroscopic unit. The principle of the method is to photograph an entire fluoroscopic exposure on the polaroid film which is rapidly developed. Since television fluoroscopic units have high gain image intensifiers and television cameras, the image produced on the television screen can easily be adjusted to be noise limited. Then, the radiation exposure to the patient would be reduced to a minumum which is about 1/100 of that for standard film radiography.

The polaroid television technique is achievable with low-cost modification of most standard television fluoroscopic units. The polaroid image is obtained in the following sequence of operations: (1) the foot-pedal is compressed, initiating the x-ray exposure, (2) the camera shutter is manually opened for a 1/2 second exposure, (3) the camera shutter automatically closes, (4) the foot-pedal is released terminating the exposure, (5) the polaroid film is developed in 15 seconds.

Since in most television chains the automatic gain control built into the television camera keep the average video output constant, the image quantum noise can be varied by changing the KVp and ma setting in the fluoroscopic exposure.

In our technique which is adapted from the orthometric pelvimetry used with standard film, a radiopaque ruler is placed between the patient and the intensifier tube. The apparatus is positioned to be centered first on one and then the other side of the anatomical structures to be measured and a polaroid fluoroscopic television image is taken. Because the field size is small, the geometric distortion is limited for each picture, and the radiation exposure is reduced from scattered radiation. The measurement of the pelvic inlet and mid-pelvis in lateral and AP views are obtained by imaging the ruler and the anatomical structure at their intersection and subtracting the two readings to obtain the distance of interest.

The fluoroscopic apparatus was slightly modified to facilitate accurate and quick measurement of the pelvis. We developed a set of clamp on lights to act as a collimator during the orthometric pelvimetry. These lights which could easily be removed at the termination of the examination, were held in place by springs and by a permanent magnet. To support the radiopaque ruler for the pelvic measurements, a plastic table was positioned on the fluoroscopic table top.

In the clinical setting, the polaroid television images of the mid-pelvis and pelvic inlet had adequate detail for the required calculations, (Fig. 4, 5). The average mid-pelvic radiation exposure to the mother in the direct beam is 1/100 of that for film cassett radiography while the fetal exposure is reduced another factor of 100. The fetal exposure reduction is a result of removing the fetus from the direct beam and from using a small field size of 4 cm x 4 cm which reduces the scattered radiation. By further reducing the field size to 2cm x 2cm for each polaroid image. We can further lower the exposure. Since the polaroid fluoroscopic television technique for pelvimetry is an inexpensive and simple method that gives adequate clinical data with a radiation exposure much reduced compared to standard radiography.



Figures 4 & 5: Polaroid Television Images of Mid-Pelvis

IV. STEREOTAXIC POSITIONING FOR NEUROSURGERY

Electronic radiography has been developed for neurosurgical procedures by coupling a two track magnetic disc recorder to a portable television fluoroscopic unit. The apparatus, enables rapid stereotaxic needle positioning for the treatment of intracranial aneurysms.

In the clinical setting for the repair of the intra-cranial aneurysm, the C-arm was placed in the AP position centered over the approximate location of the aneurysm. First, the apparatus was switched into the "MAP" mode and an electronic angiogram showing the location of the aneurysm was made. Then with the apparatus switched into the mode "STORED + MAP" successive electronic images were taken showing the needle guide superimposed with the frozen image of the aneurysm as the guide was moved into position, (FIG. 6). After positioning had been completed, the stereotaxic needle was inserted through the skull into the aneurysm. To monitor this insertion, the apparatus was placed in a lateral position and a new angiogram, taken in the MAP mode, was superimposed with the needle as it was advanced through the brain into the aneurysm using the FLUORO - MAP mode. Tissue adhesive was injected into the aneurysm via the needle. Using the FLUORO mode the extent of occlusion of the aneurysm was evaluated by injecting contrast material into the carotid artery to outline the vessel.

The electronic technique permits successful localization and treatment of an intracranial aneurysm with procedure time and patient trauma markedly reduced compared to the **traditional craniotomy.**

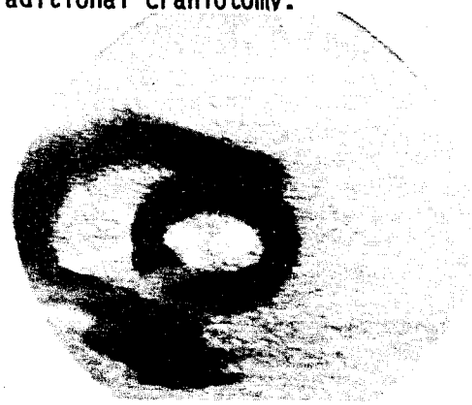

Figure 6: Electronic Radiograph of Stereotaxic Needle Guide Superimposed with the Electronic Angiogram of the Aneurysm

The radiation dose to the patient for each electronic radiograph was 1/100 of that for one minute of continuous fluoroscopy. By superimposing single electronic radiographs on a stored map, the surgeon required only a few images, each of the order of a milliroentgen significantly reducing the radiation exposure to personnel in the operating room.

V. SELECTIVE CATHETERIZATION

By coupling a 150 track disc recorder to a plumbicon television fluoroscopic unit, we have developed electronic radiography for selective catheterization to reduce procedure time, radiation exposure, and the volume of injected radiopaque contrast material. There are three levels of refinement of electronic catheterization which can be applied depending on the degree of difficulty encountered in the procedure. These

methods have been clinically applied to selective catheterization of both neuro and visceral vessels.

A. Individual Electronic Radiograph

In this technique the angiographer takes a single electronic radiograph which he studies with the x-rays off to determine the amount and direction the catheter should be manipulated to achieve successful selective catheterization. These images showing the catheter relative to bony landmarks such as vertebrae and ribs substitute for live fluoroscopy. The progress of the manipulated catheter can be recorded on successive electronic radiographs.

B. Electronic Radiograph Guided by Map

An electronic angiogram is recorded during an aortic injection of radiopaque contrast. The arterial map showing the aorta with the branch vessel is electronically combined with successive individual electronic images of the catheter and the combined image is displayed over the TV monitor. By studing the position of the catheter tip relative to the branch blood vessel, the angiographer can evaluate the amount and direction of repositioning required for successful selective catheterization.

C. Arterial Map with Live Image Superimposed

This method, as in the previous one, uses the electronic angiogram (arterial map) as a guide for selective catheterization. In this method however the live fluoroscopic image of the catheter is electronically superimposed on the map. In a preliminary clinical trial in 20 patients, the three variations described were found to simplify the procedure and reduce the radiation dose. By obviating the need for repeated test injections of radiopaque contrast, the electronic arterial maps greatly decreased the total amount of contrast injected during catheterization. By utilizing a series of images stored on a magnetic disc, electronic radiography replaces continuous live fluoroscopy by the production of electronic images requiring much less radiation than that for conventional fluoroscopy. This technique reduces procedure time, radiopaque contrast, and the radiation exposure.

VI. CONCLUSION

In the proper clinical setting electronic radiography will reduce the radiation exposure from 10 to 10,000 times of that with standard techniques in diagnostic radiology. The principle advantages of this method are that the clinical information determines the level of radiation exposure required and as a consequence of the efficient use of radiation various image enhancement techniques will yield a final electronic image with higher resolution and contrast than standard spot films in some cases. In addition to these advantages electronic radiography is convenient and opens the way for new treatment methods.

References

1. D. Sashin, et. al., "Resolution Contrast and Dose Reduction Performance of Electronic Radiographic Systems", 2nd Intl. Conf. on Med. Physics, Boston, Mass., 1969.

2. Ionizing Radiation: Levels and Effects, U.N. Vols. 1 & 2, E.72.IX.18, N.Y., 1972.

3. A.Stewart, G.W. Kneale, "Radiation Dose Effects in Relation to Obstetric X-rays and Childhood Cancers", The Lancet, 11:1185, 1970.

4. The Effects on Populations of Exposure to Low Levels of Ionizing Radiation, Environ. Prot. Agency & Dept. of H.E.W., Washington, 1972.

5. D. Sashin, W.Short, E.R. Heinz, and E.J. Sternglass, "Electronic Radiology for Spot Filming in Gastrointestinal Fluoroscopy", Radiology, 106:551-553, 1973.

6. D.Sashin & K. Bron, "Electronic Selective Catheterization", Radiology (to be published).

7. D. Sashin,S.S.Yaniv, J. Mazer & E.J.Sternglass, "Pelvimetry with Negligible Fetal Radiation Exposure" Proc. of Symp. in Health Physics in the Healing Arts, Dec. 1972.

8. D.Sashin, et.al., "Electronic Radiology in Stereotaxic Thrombosis of Intracranial Aneurysms and Catheter Embolization of Cerebral A-V Malformations", Radiology, 105:359-363, 1972.